



## ASSESSMENT OF FISH HEALTH STATUS UNDER LONG-TERM WATER POLLUTION: VYGOZERO RESERVOIR, NORTH-WEST RUSSIA

**Lidia A. Belicheva, Julia N. Sharova**

Northern Water Problems Institute, Karelian Research Centre, Russian Academy of Science  
Nevsky st., 50, Petrozavodsk, 185035, Russia

Ph.: +78142576520, fax: +78142578464, e-mail: belicheva.lida@yandex.ru

---

**Abstract.** *Environmental pollution and its effects on the health of aquatic ecosystems is a great problem that has been studied intensely in the last years. The Vygozero reservoir is one of the largest water bodies of the Karelian Republic. Its ecosystem has undergone significant changes since the 1930s mainly due to anthropogenic influence from the development of pulp and paper mill industry leading to accumulation of toxic contaminants and eutrophication. At present, the water body has been shown to be also polluted by hydrocarbon products and heavy metals. Among the huge changes in Vygozero ecosystem is the decrease of some fish populations and partial loss of commercial fishing importance. Despite the obvious changes in fish population the chronic biological effects of the Vygozero reservoir pollution on fish organism are poorly studied. This study is concerned with the evaluation of pollution influence on fish health status and establishment relation between fish health and environmental quality. The parameters selected for this aim were the occurrence of gills, liver and kidney alterations, as histopathological changes are widely used as biomarkers in the evaluation of the health of fish exposed to contaminants. Our findings confirm chronic pollution of the Vygozero reservoir. Histological analysis of fish tissues revealed a variety of progressive, regressive, inflammatory, circulatory disturbances and neoplastic changes. Observed histological alterations indicate that organism of fish from Vygozero reservoir responds to the impaired environment quality. Revealed histopathologies are signs of metabolic disorders, immunity suppression, compensatory reactions development and functional abnormalities in vital organs of studied fish. The results of the study correspond to the prior research devoted to ascertain tissue changes in different fish species taken from an area with chronic multiple anthropogenic impact. So it can be concluded that histopathological lesions are result of long-term effect of toxic xenobiotics.*

**Keywords:** *gill, liver and kidney histopathology, pollution.*

---

### Introduction

The Vygozero reservoir is one of the largest water bodies of the Karelian Republic. Its ecosystem has undergone significant changes since the 1930s mainly due to anthropogenic influence from the development of pulp and paper mill industry leading to accumulation of toxic contaminants and eutrophication [1]. At present, the wastes discharging to the water body has been shown to be polluted by excessive concentrations of hydrocarbon products, ammonia, heavy metals [2,3]. The increase of anthropogenic load on Vygozero ecosystem determines the necessity of investigations devoted to adverse effects of pollution and its potential risk for aquatic ecosystems.

Deleterious effects of the water body pollution have already been detected on populations of different organisms inhabited Vygozero reservoir [3]. The decrease of some fish populations and partial loss of commercial fishing importance are among of the huge changes in Vygozero ecosystem. It is a well known fact that biochemical, cellular, tissue, and organism modifications underlines different types of ecosystem changes; however the chronic biological effects of the Vygozero reservoir pollution on fish organism are poorly studied. The exposure of fish to chemical contaminants induces a number of modifications in different organs, particularly gills, liver and kidney. Therefore a wide range of histo-cytological alterations in fish have been developed and recommended as biomarkers for monitoring the pollution [4-6]. This study is concerned with the evaluation of pollution influence on fish health status and establishment relation between fish health and environmental quality on the base of histological examination.

### Materials and methods

In the autumn of 2007 and 2010 a total of 26 individuals of bream (*Abramis brama* L.), roach (*Rutilus rutilus* L.), perch (*Perca fluviatilis* L.) and sander (*Stizostedion lucioperca* L.) were caught. Sex, standard length, and weight of all fish were recorded. Fish were dissected directly in the field, and the target organs (liver, kidney and gills) were quickly removed. Histological techniques were performed according to Bucke [7]. After fixation in Bouin's solution for a week at room temperature, tissues were dehydrated and routinely processed for paraffin embedding. Then, 5–7 mm thick sections were made in a rotary microtome and stained with hematoxylin and eosin. Tissues were screened for a variety of histopathological features and lesions under 50, 100, 200 magnification.

### Results

A variety of histopathological changes were found in all organs examined. The gill, liver and kidney structure of species used in this study are well known and similar to those in other teleosts (Fig. 1a, e, i).

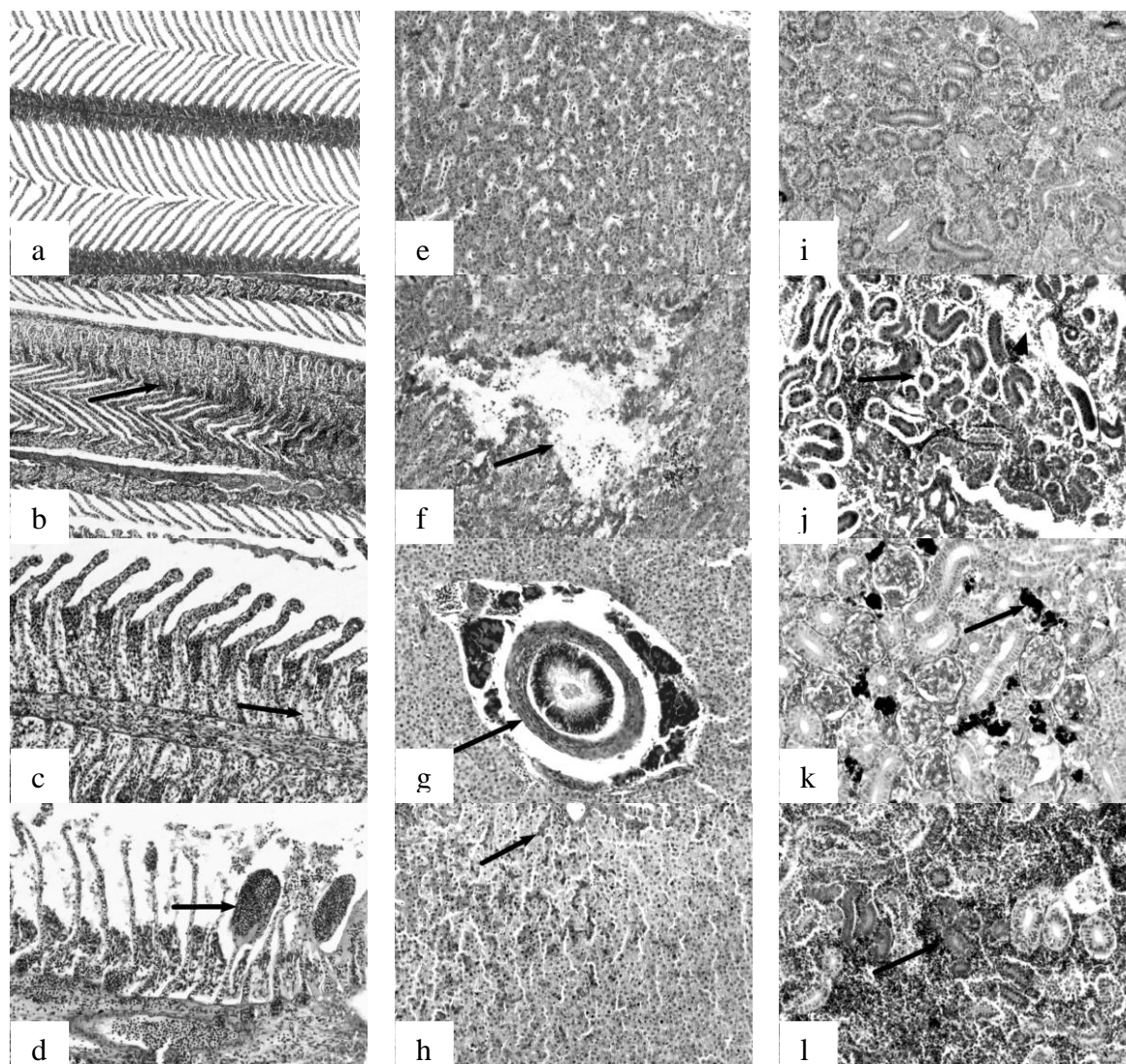
The microscopic structure of almost all investigated fish showed similar gill lesions with variable severity. In the gills, epithelial cells hyperplasia, marked by proliferation epithelium on the tips of the secondary lamellae (Fig. 1b) and interlamellar zones, epithelial lifting, accompanied by the enlargement of the intertissue space between the epithelium and underlying pillar cells, and hyperemia of blood vessels were the predominant alteration. Focal areas of necrotic epithelial cells found at the base of the respiratory lamellae (Fig. 1c) as well as necrosis of respiratory epithelium associated by full destruction of respiratory lamellae were also a very common finding.

Some fish from Vygozero reservoir shows cellular vacuolization and hypertrophy, lamellar shortening and clubbing, aneurisms and local hemorrhages with rupture of epithelial cells (Fig. 1d), intravascular breakdown of erythrocytes, eosinophilic deposits and mucus secretion. Rarely inflammatory reactions, marked by infiltration of the inflammatory cells, and fibrosis, resulted in partial destruction of filaments and gills function loss, were revealed.

Another kind of gill pathology was induced by parasite invasion. Several kinds of endo- and ecto-parasites infesting studied fish gills were observed. The most common includes unspecified microsporidia and ciliates. Ciliates usually did not elicit any visible host response, while microsporidia led to the formation of xenomas – hypertrophied host cells which contain spores and other developmental stages of parasite. Usually xenomas induced cellular hypertrophy, and as nuclear fragmentation, organelles changes others structural alterations.

The microscopic structure of fish liver also shows a number of injuries. In the liver of fish from Vygozero reservoir necrotic lesions, indicated by pyknotic hepatocyte nuclei, focal and single cell necrosis (Fig. 1f), were more common than other pathologies. In several fish degenerative changes also include appear of vacuolated cells, characterized presence of large lipid vacuoles, which usually occupied the whole cell and displaced nuclei to the periphery, and cystic degeneration. Many fish from Vygozero reservoir also exhibited inflammatory alterations, judged by macrophages aggregates and inflammatory cell infiltration around blood vessels, hyperemia of blood vessels and erythrocytes destruction.

Some studied fish had signs of liver neoplastic changes. Affected hepatocytes had features of varying degrees of cellular pleomorphism, nuclear atypia, high mitotic activity and abnormal architecture. Presence of non-neoplastic proliferative changes, represented by small islands regenerating hepatocytes, which were markedly basophilic and lacked cytoplasmic vacuoles, was also seen in fish (Fig. 1h). In a few fish small foci of hemorrhages, thickened walls of blood vessels and initial stage of thrombus formation were revealed.



**Fig 1. Histological sections of gill, liver and kidney of fish from the Vygozero reservoir (H&E):**

**(a) Gill tissue without lesions, x100; (b) epithelial hyperplasia (arrow), x100; (c) necrosis of epithelial cells (arrow), x200; (d) aneurisms (arrow), x200; (e) hepatic tissue without lesions, x200; (f) necrosis area (arrow), x200; (g) bile duct fibrosis (arrow), x200; (h) regenerative islands of hepatocytes (arrow), x200; (i) kidney tissue without lesions, x200; (j) foci of interstitial tissue necrosis (arrowheads) and detachment of epithelial cells from the underlying tubular basement membrane (arrow), x200; (k) melanomacrophage centers (arrow), x200; (l) developing nephrons (arrow), x200**

The bile ductules of studied fish were frequently damaged. Mild to moderate bile ducts fibrosis and necrosis of epithelial cells, evidenced by the presence of epithelial desquamation and small amounts of debris, was frequent enough (Fig. 1g).

Another pathology observed in the liver of Vygozero fish was parasite invasion. Usually infected fish contain from 1 to 3 parasite cysts, which induced inflammatory connective tissue proliferation.

In the posterior kidney of fish alterations were observed in all segments of the nephron, the interstitial tissue, the vascular system and the immune system. The most consistently observed histopathologies in interstitial tissues were hemorrhages, foci of necrosis (Fig. 1j), and increased number of macrophages aggregates with two types of pigments (melanin and hemosiderin) (Fig. 1k). Such pathologies as blood vessel hyperemia, thickened walls of blood

vessels, breakdown of erythrocytes, fibrosis of interstitial tissue, appearance of lipid cells, and development of granulomas and new nephrons (Fig. 11) were also a common finding.

Among the signs of glomerular injury, mesangial cells proliferation and capillary dilation were the most common, while glomerular 'hyalinization' and shrunken glomerular tuft with dilation of Bowman's space was observed quite rare. In studied fish species glomerular necrosis was also frequent enough.

The tubular effects include detachment of the epithelial cell from the underlying basement membrane (Fig. 1j), debris and eosinophilic mass accumulation in tubular lumina, fibrotic proliferation around tubules, epithelial cells necrosis, vacuolization and nuclear piknosis. It should be noted that all mentioned pathologies were focal or even single.

In kidney of several fish parasite cysts and unspecified myxosporea in renal collecting ducts were also observed.

### **Discussion**

This paper presents the results of gills, liver and kidney histopathological investigation of fish from Vygozero reservoir. Being among the first organs to be affected by contaminants and very sensitive to changes, gill, liver and kidney, are important indicators of fish health and, therefore, environmental pollution [8-10].

The high incidence of histological alterations in the gill, liver and kidney is an evidence of the poor environmental quality. The types of histopathological lesions observed in this study indicate that fish from Vygozero reservoir respond to both direct toxicant effects of contaminated water and sediments and secondary stress effects caused by factors such as parasitism. Most of the histopathological alterations observed in the present study (e.g. hyperplasia and lifting of epithelial cells in gills; hepatocellular necrosis, vacuolization and cystic degeneration in liver; glomerulonephritis, haemorrhages and necrosis in kidney, etc.) could be interpreted as a nonspecific response to stress and are described in fish exposed to a wide spectrum of pollutants.

Thus most of the gill structural modifications found in this study were previously reported for many unrelated toxicants such as heavy metals [11, 12], pulp and paper mill effluents [13, 14], crude oil [15], excessive ammonia concentrations [18, 19]. A number of investigations have showed that many of observed liver alteration, e.g. focal and diffuse vacuolar degeneration of hepatocytes, foci of necrosis, regeneration and inflammation, hepatocytes with piknotic nuclei, etc., can be a result of fish exposure to a variety of different chemical compounds, such as crude oil, pulp and paper mill effluents, excessive ammonia concentrations, heavy metals and complex environmental pollution [9, 12, 14, 15, 16, 18]. In the kidney, different signs of tubule and glomerular degenerations, developing nephrons and macrophage aggregates were also described in fish exposed to heavy metals [12, 17], excessive ammonia concentrations [18], effluents of pulp and paper mill [14], and mixed environmental contaminants [9, 20]. Thus, all of known pollutants of Vygozero reservoir could induce revealed histopathological alterations in studied fish.

As some parasites of fish are sensitive to environmental changes, they can also be useful as biomarkers of environmental health [21, 22]. Ectoparasites (e.g. gill ciliates) are good examples of this effect since they intensity or prevalence increase with oil pollution, pulp and paper mill and industrial effluents [14, 21-25]. On the whole, observed abundance of the parasites coincided with pathological changes on the one hand suggest prolonged exposure and on the other hand confirm the fact of the reservoir pollution.

Revealed structural changes in gills, liver and kidney testify that environmental changes induce fish organism response. And there are two main types of structural changes: one is direct toxic effect of the pollutant leading to tissue degeneration and necrosis, and the other is the development of compensatory mechanisms to deal with the stressors. Thus, such pathological changes as epithelial hyperplasia, hypertrophy, and lifting are considered as defense mechanisms, as they increase the distance between external environment and the

blood and thus serve as barrier to the entrance of xenobiotics [8, 26]. However development of such alterations also leads to decrease of total diffuse surface and oxygen uptake, and, therefore, hypoxia. So hepatic degeneration and necrosis of fish liver partly may be due to oxygen deficiency as a result of the gill changes in the gill surface area.

Our findings demonstrate strongly that fish of the Vygozero reservoir were under long-term chronic pollution as much as accidental exposure. Such pathologies as aneurysm, hepatocellular vacuolization, new developing nephrons and swelling of tubular epithelium are known to be an acute response of organism. At the same time, the presence of epithelial hyperplasia and fibrosis in the gills; fibrosis and tubule degeneration, coupled with necrosis in the kidney; and fibrosis of bile duct, necrosis, vacuolization and cystic degeneration in the liver indicates that studied fish are exposed to long-term chronic pollution.

### **Summary**

Histological alterations indicate that organism of fish from Vygozero reservoir response to the impaired environment quality. Revealed histopathologies are signs of metabolic disorders, immunity suppression, compensatory reactions development and functional abnormalities in vital organs of studied fish. The results of the study correspond to the prior research devoted to ascertain tissue changes in different fish species taken from an area with chronic multiple anthropogenic impact. So it can be concluded that histopathological lesions are result of long-term effect of toxic xenobiotics.

### **References**

1. Losovik, P.A. Ecological problems of the Segezha-Nadvoitsy industrial hub. In: The water environment of Karelia: research, management and conservation, Petrozavodsk, 2003, p.26-34. (in Russian)
2. State report on environment state in Republic of Karelia in 2008. Petrozavodsk, 2009, 288 p. (in Russian)
3. Status of water objects in Republic of Karelia according to 1998-2006 monitoring results. Petrozavodsk, 2007, 210 p. (in Russian)
4. Bernet, D., Schmidt, H., Meier, W., Burkhardt-Holm, P., Wahli, T. Histopathology in fish: proposal for a protocol to assess aquatic pollution. *J. Fish Dis.*, 22, 1999, p.25-34.
5. Cooley, H.M., Evans, R.E., Klaverkamp, J.F. Toxicology of dietary uranium in lake whitefish (*Coregonus clupeaformis*). *Aquat. Toxicol.*, 48, 2000, p.495-515.
6. Au, D. W. T. The application of histo-cytopathological biomarkers in marine pollution monitoring: a review. *Mar. Poll. Bull.*, 48, 2004, p.814-834.
7. Bucke, D., Methodologies for demonstrating pathological changes in flounder (*Platichthys flesus* (L.)). In: *Diseases and Parasites of Flounder in the Baltic sea*, BMB Publ., 15, 1994, p.131-143.
8. Hinton, D. E., & Laurén, D. J. Liver structural alterations accompanying chronic toxicity in fishes. Potential biomarkers of exposure. In: *Biomarkers of Environmental Contamination*, 1990, p.17-57.
9. Schwaiger, J., Wanke, R., Adam, S., Pawert, M., Honnen, W., Triebkorn, R. The use of histopathological indicators to evaluate contaminant-related stress in fish. *J. Aqua. Ecosyst. Stress Recovery*, 6, 1997, p.75-86.
10. Triebkorn, R., Telcean, I., Casper, H., Farkas, A., Sandu, C., Stan, G., Colarescu, O., Dori, T., Kohler, H.-R. Monitoring pollution in River Mures, Romania, part II: metal accumulation and histopathology in fish. *Environ. Monit. Assess.*, 141, 2008, p.177-188.
11. Pandey, S., Parvez, S., Ansari, R.A., Ali, M., Kaur, M., Hayat, F., Ahmad F., Raisudinn, S. Effects of exposure to multiple trace metals on biochemical, histological and ultrastructural features of gills of a freshwater fish, *Channa punctata* Bloch. *Chemico-Biological Interactions*, 174, 2008, p.183-192
12. Giari, L., Manera, M., Simoni, E., Dezfuli, B.S. Cellular alterations in different organs of European sea bass *Dicentrarchus labrax* (L.) exposed to cadmium. *Chemosphere*, 67, 2007, p.1171-1181.
13. Lehtinen, K.J., Notini, M., Landler, L. Tissue damage and parasite frequency in flounders, *Platichthys flexus*, chronically exposed to bleached kraft pulp mill effluents. *Ann. Zool. Fenn.*, 21, 1984, p.23-28.
14. Khan, R.A., Barker, D.E., Hooper, R., Lee, E.M., Ryan, K., Nag, K. Histopathology in winter flounder (*Pleuronectes americanus*) living adjacent to a pulp and paper mill. *Arc. Environ. Contam. Toxic.* 26, 1994, p.95-102.
15. Brand, D.G., Fink, R., Bengueyfield, W., Birtwell, I.K., McAllister, C.D., Salt wateracclimated pink Salmon Fry (*Oncorhynchus gorboscha*) develop stress-related visceral lesions after 10-day exposure to sublethal concentrations of the watersoluble fraction of north slope crude oil. *Toxicol. Pathol.*, 29, 2001, p.574-584.
16. Sepulveda, M.S., Gallagher, E.P., Gross, T.S. Physiological changes in largemouth bass exposed to paper mill effluents under laboratory and field conditions. *Ecotoxicology*, 13, 2004, p.291-301.

17. Mishra, A.K., Mohanty, B. Acute toxicity impacts of hexavalent chromium on behavior and histopathology of gills, kidney and liver of the freshwater fish., *Channa punctatus* (Bloch). *Ecotox. Environ. Saf.*, 26, 2008, p.136-141.
18. Benli, A.C.K., Köksal, G., Özkul, A. Sublethal ammonia exposure of Nile tilapia (*Oreochromis niloticus* L.): Effects on gill, liver and kidney histology. *Chemosphere*, 72, 2008, p.1355-1358.
19. Spencer, P., Pollock, R., Dube, M. Effects of un-ionized ammonia on histological, endocrine, and whole organism endpoints in slimy sculpin (*Cottus cognatus*). *Aquat. Toxicol.*, 90, 2008, p.300-309
20. Camargo, M.M.P., Martinez, C.B.R. Histopathology of gills, kidney and liver of a Neotropical fish caged in an urban stream. *Neotropical Ichthyology*, 5, 2007, p.327-336
21. Khan, R.A., Thulin, J. Influence of pollution on parasites of aquatic animals. *Adv. Parasitol.*, 30, 1991, p.201-238
22. Yeomans, W.E., Chubb, J.E., Sweeting, R.A. Use of protozoan communities for pollution monitoring. *Parassitologia*, 39, 1997, p.201-212.
23. Lehtinen, K.-J. Survival, growth and disease of three-spined stickleback, *Gasterosteus aculeatus* L., brood exposed to bleached kraft mill effluents (BKME) in mesocosms. *Ann. Zool. Fenn.*, 26, 1989, p.133-144
24. Overstreet, R.M., Howse, H.D., Some parasites and diseases of estuarine fishes in polluted habitats of Mississippi. *Ann. New York Acad. Sci.*, 298, 1977, p.427-462.
25. Khan, R.A., Parasitism in marine fish after chronic exposure to petroleum compounds in the laboratory and to the Exxon Valdez oil spill. *Bull. Environ. Contam. Toxicol.*, 44, 1990, p.759-763.
26. Mallat, J. Fish gill structural changes induced by toxicants and other irritants: a statistical review. *Canadian Journal of Fish and Aquatic Science*, 1985, 42, p.630-648.